

AccessDermatologyDxRx User Guide

맥그로힐 한국지사


What is AccessDermatologyDxRx?



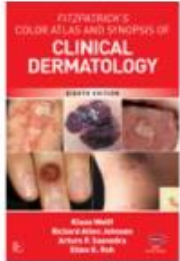





- AccessDermatologyDxRx는 의대생, 피부과 레지던트, 내과 전문의, 종양 전문의 및 전염병 전문가를 포함한 모든 의사 및 기타 의료 제공자를 위한 포괄적인 리소스입니다.
- 이 리소스는 피부 질환의 전체 범위를 다루며, 임상 의사 결정에 도움이 되는 모든 필수 정보가 포함된 수천 개의 이미지가 포함되어 있습니다.
- Brief Overview: <https://youtu.be/6X91gVa5xfc>




What is AccessDermatologyDxRx?

ACCESS DermatologyDxRx™


Books Quick Reference ▾ Drugs Multimedia ▾ Cases ▾ Patient Ed Study Tools ▾ About ▾

AccessDermatologyDxRx ▾ Search AccessDermatologyDxRx  About Search




 Browse Books by Topic  Get Alerts 

Discover




Includes access to

Skin of Color Content




Animated Derm Modules



AccessDermatologyDxRx : Key Features

- **25+ Textbook** 핵심 피부과학 제공
- **700+ Review Questions** (다양한 Q&A test를 통해 학습상황 확인 및 강점, 약점 파악)
- **400+ 멀티미디어 자료** (애니메이션, biopsies, 피부과수술, 봉합기술 등의 내용을 포함)
- **Cases** (Clinical Dermatology cases - 1차 진료 시 흔히 볼수 있는 다양한 사례와 임상사진, 진단옵션 등을 제공)
- **1,000+ Drug** 정보

Front page





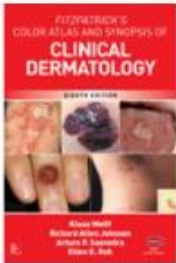





Menu bar


Books Quick Reference ▾ Drugs Multimedia ▾ Cases ▾ Patient Ed Study Tools ▾ About ▾



Search

AccessDermatologyDxRx ▾ Search AccessDermatologyDxRx


About Search



 Browse Books by Topic


 Get Alerts 

Discover




Includes access to

Skin of Color Content



Animated Derm Modules



Search - 키워드 검색

검색결과에서 결과 좁히기
1. Modify Search의
검색상자에 키워드를 입력 후
Update 클릭하여 결과좁히기
(Add term으로 추가 가능
2. 필터를 통해 필요한 항목만
체크(포맷, 텍스트북, 토픽)

키워드로 검색된
- 자료 유형
- 유형별 결과 수

수록교재로 분류

토픽별로 분류

1-20 of 63 Search Results for

Rickettsial Diseases

[Search Rickettsial Diseases across all McGraw Hill Medical sites >](#)

Modify Search

Keyword

Rickettsial Diseases

+ Add Term

Update

Filter Results

FORMAT

<input type="checkbox"/> Book Chapter	47
<input type="checkbox"/> Tables	11
<input type="checkbox"/> Images	4

SELECT TEXTBOOKS

Select Textbooks

TOPICS


Topics

☐ venous thromboembolism (59)

☐ pulmonary embolism (47)

☐ therapeutics (47)


키워드 검색 시 사례
: 사용자가 Rickettsial Diseases와
같이 두 단어를 검색하면 두 단어가
and 검색으로 이루어진 결과를 보여줌



BOOK CHAPTER

Treponemal and Rickettsial Diseases


Book: Barnhill's Dermatopathology, 4e



BOOK CHAPTER

Spirochetal, Protozoal, Mycobacterial, and Rickettsial Diseases


Book: Weinberg's Color Atlas of Pediatric Dermatology, 5e



BOOK CHAPTER

RICKETTSIAL INFECTION


Book: Color Atlas & Synopsis of Pediatric Dermatology, 3e



BOOK CHAPTER

The Rickettsioses, Ehrlichioses, and Anaplasmoses

Book: Fitzpatrick's Dermatology, 9e



BOOK CHAPTER

Books : 원문보기

ACCESS DermatologyDxRx™

Access Provided by: McGraw Hill Medical

Books Quick Reference ▾ Drugs Multimedia ▾ Cases ▾ Patient Ed Study Tools ▾ About ▾

AccessDermatologyDxRx ▾ Search AccessDermatologyDxRx

Books

Library ▾

- Board Review
- Burns and Scars
- Clinical Dermatology
- Cosmeceuticals
- Cosmetic Dermatology
- Dermatologic Surgery
- Dermatopathology
- Dermoscopy
- General Dermatology
- Graduate Medical Education
- Pediatric Dermatology
- Skin of Color
- Venous Insufficiency

Textbooks

Tools ▾

Grid List

Fitzpatrick's Dermatology, 9e

Sewon Kang, Masayuki Amagai, Anna L. Bruckner, Alexander H. Enk, David J. Margolis, Amy J. McMichael, Jeffrey S. Orringer

Atlas of Suturing Techniques: Approaches to Surgical Wound

Jonathan Kantor

Barnhill's Dermatopathology Challenge: Self-Assessment & Review

Garrett's Dermal


Barnhill's Dermatopathology, 4e

Raymond L. Barnhill, A. Neil Crowson, Cynthia M.

Book-Library를 통해 모든 교재 리스트를 보거나, 주제별로 Filtering하여 도서 검색

Books : 원문보기

Home > Books >



Fitzpatrick's Dermatology, 9e

Sewon Kang, Masayuki Amagai, Anna L. Bruckner, Alexander J. McMichael, Jeffrey S. Orringer

해당 교재 내 검색

Search Textbook



Show Chapters Hide Chapters

+ PART 1: FOUNDATIONS OF CLINICAL DERMATOLOGY

- PART 2: STRUCTURE AND FUNCTION OF SKIN

Chapter 4: Developmental Biology of the Skin

Chapter 5: Growth and Differentiation of the Epidermis

Chapter 6: Skin Glands: Sebaceous, Eccrine, and Apocrine Glands

Chapter 7: Biology of Hair Follicles

Chapter 8: Nail

Chapter 9: Cutaneous Vasculature

Chapter 10: The Immunological Structure of the Skin

Chapter 11: Cellular Components of the Cutaneous Immune System

Chapter 12: Soluble Mediators of the Cutaneous Immune System

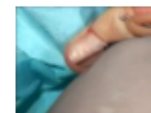Chapter 13: Basic Pathophysiology of Inflammation in Skin (Pathophysiology of Immunologic/Inflammatory Skin Diseases)

챕터별 보기

FEATURES

Multimedia

Video 205-2.
3 mins, 28 secs



Video 159-2.
1 min, 34 secs



Video 159-3.
20 secs



View All Videos

연관된
Multimedia 자원

Copyright

Notice

Editors

Contributors

Preface


Acknowledgments

도서 기본정보

Books : 원문보기

Home > Books > Fitzpatrick's Dermatology, 9e >

◀ Previous Chapter | Next Chapter ▶



Chapter 4: Developmental Biology of the Skin

Luis Garza

인쇄, 공유, 인용, 책 내
검색 등의 부가기능 제공

Sections

Download Chapter PDF

Share

Get Citation

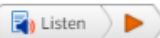Search Book

Full Chapter

Figures

Tables

— KEYWORDS



- Cell lineage: The family tree history of a cell through all of its divisions.

- Clone: Any distinct cell and all of its progeny.

- Differentiation: The process where a cell becomes increasingly specialized in their cellular lineage. The least-differentiated cells are the totipotent embryonic stem cells which can develop into any cell in the body. The most differentiated cells are restricted to their type and have the least potential to become

Search Book 클릭 시
검색창이 나타남

원문내용

Books : 원문보기

Expand All Sections
Jump to a Section

INTRODUCTION
APPROACH TO THE PATIENT
ACUTE BACTERIAL ARTHRITIS
PATHOGENESIS
MICROBIOLOGY
NONGONOCOCCAL BACTERIAL ARTHRITIS
TREATMENT
GONOCOCCAL ARTHRITIS
TREATMENT
SPIROCHETAL ARTHRITIS
LYME DISEASE
TREATMENT
SYPHILITIC ARTHRITIS
MYCOBACTERIAL ARTHRITIS
FUNGAL ARTHRITIS
VIRAL ARTHRITIS
PARASITIC ARTHRITIS
POSTINFECTIOUS OR REACTIVE ARTHRITIS
INFECTIONS IN PROSTHETIC JOINTS
TREATMENT

Books Quick Reference Drugs Multimedia Cases Study Tools Patient Ed Hospital Corner

AccessMedicine Search AccessMedicine

Home > Books > Harrison's Principles of Internal Medicine, 20e >

Chapter 125: Infectious Arthritis

Lawrence C. Madoff

Sections Print Share Get Citation Search Book

목차 : “Section” 클릭 시 왼쪽에 각 section 리스트가 나타나고, 클릭하여 바로 이동할 수 있음


Listen

Although *Staphylococcus aureus*, *Neisseria gonorrhoeae*, and other bacteria are the most common of infectious arthritis, various mycobacteria, spirochetes, fungi, and viruses also infect joints (Table 125-1). Since acute bacterial infection can destroy articular cartilage rapidly, all inflamed joints must be evaluated without delay to exclude noninfectious processes and determine appropriate antimicrobial therapy and drainage procedures. For more detailed information on infectious arthritis caused by specific organisms, the reader is referred to the chapters on those organisms.

TABLE 125-1
Differential Diagnosis of Arthritis Syndromes

Books : 원문보기

Home > Books > Harrison's Principles of Internal Medicine, 20e > Previous Chapter



Chapter 125: Infectious Arthritis

Lawrence C. Madoff

Sections Print Share Get Citation Search Book

Full Chapter Figures Tables

INTRODUCTION

Listen [audio player controls] Speech-enabled by ReadSpeaker

Although *Staphylococcus aureus*, *Neisseria gonorrhoeae*, and other bacteria are the most common causes of infectious arthritis, various mycobacteria, spirochetes, fungi, and viruses also infect joints (Table 125-1). Since acute bacterial infection can destroy articular cartilage rapidly, all inflamed joints must be evaluated without delay to exclude noninfectious processes and determine appropriate antimicrobial therapy and drainage procedures. For more detailed information on infectious arthritis caused by specific organisms, the reader is referred to the chapters on those organisms.

TABLE 125-1
Differential Diagnosis of Arthritis Syndromes

Listen 기능 :
텍스트를 음성으로 읽어주는 도구로, 각 챕터 섹션의 시작 부분에서 제공됨

톱니모양 아이콘을 클릭하면 읽어주는 속도, 하이라이트 표기 여부, 컬러 등 설정 가능

Quick Reference : Fitzpatrick's Flashcard Images

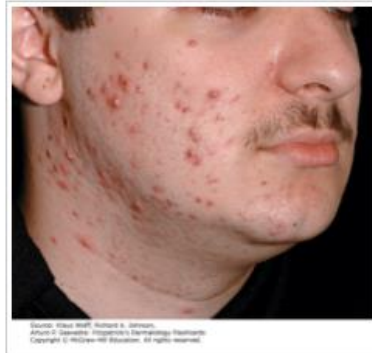
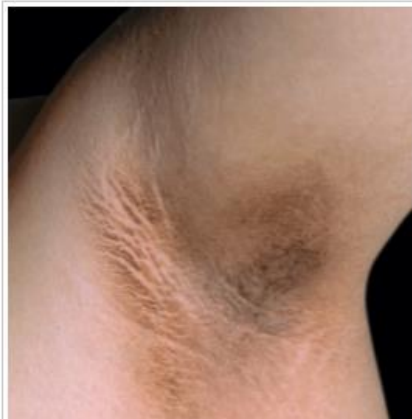신속한 참조와 임상 환경에서 진단이 용이하도록 Fitzpatrick's Dermatology Flashcards의 강력한 이미지 갤러리를 제공합니다.

이미지는 프레젠테이션 및 교육 목적으로 저장 및 다운로드할 수 있습니다.



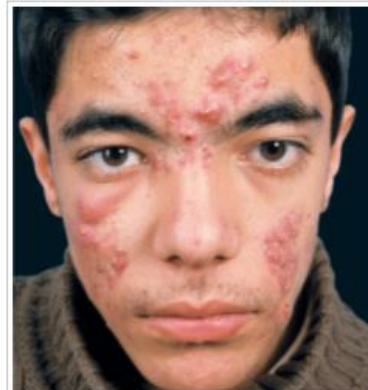Fitzpatrick's Flashcard Images

The content that appears below is from Fitzpatrick's Dermatology Flashcards.

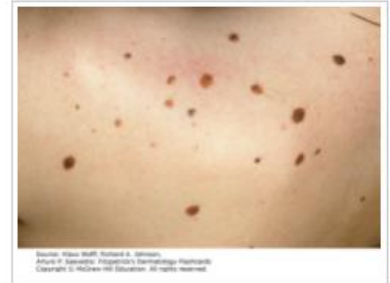

ACNE

Occurs commonly affecting



Source: Klaus Wolff, Richard A. Silvers, et al. Fitzpatrick's Dermatology Flashcards. Copyright © McGraw-Hill Education. All rights reserved.



ACQUIRED NEVOMELANOCYTIC NEVI

Acquired nevi, also called moles, are one of the most common acquired growths in light-

Drugs

Drug Monographs

- All Drugs
- Generics
- Trade Names
- Drug Classes
- Patient Handouts

All Drugs

0-9 A B C D E F G H I J K L M N O P Q R S T U V W X Y Z

A&D Jr. [OTC]

A.E.R. Traveler [OTC]

A.E.R. Wi

A-200 Lic

A-25 [OTC]

AA-Cloza

Abacavir,

Abalopar


Drug Monographs

- All Drugs
- Generics
- Trade Names
- Drug Classes
- Patient Handouts

All Drugs > K

Ivacaftor

- Basics
- Clinical Pharmacology
- Indications & Usage
- Contraindications
- Warnings/Precautions
- Pregnancy & Lactation
- Adverse Reactions
- Interactions
- Dosing
- Administration
- Storage & Compatibility
- Monitoring
- Patient Education
- Additional Information
- Pricing
- References

Images	Description
 <div>Formulation Details</div>	Kalydeco [VERTEX PHARMACEUTICALS, INC.] 150 mg
<div>View all</div>	

Name
Ivacaftor

Pronunciation
(eye va KAF tor)

Brand Names: US

1,000+종 이상의 약물정보 제공
복용방법, 적응증, 부작용, 가격정보 등

- Indications and Usage
- Contraindications
- Warning/Precautions
- Dosing
- Administration
- Patient Education handouts
- Interactions

Multimedia : Videos

Multimedia

Animations

Biopsies

Clinical Dermatology

Dermatologic Surgery

General Dermatology

Suturing Techniques

Vein Treatment


Tools ▾

Animations



Acanthosis Nigricans

Play



Acne

Play



Basal Cell

다양한 멀티미디어 콘텐츠를
제공하여 강의와 학습을 위해
지원합니다.

Basal Cell Carcinoma on Face

Share

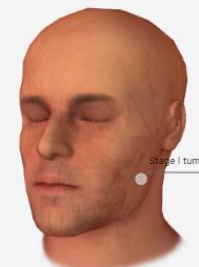1. Basal Cell Carcinoma: Stage I ▾

The presence of any nonhealing lesion should raise the suspicion of skin cancer. Basal Cell Carcinoma (BCC) usually develops on sun-exposed areas of the head and neck but can occur anywhere on the body. Commonly seen features include translucency, ulceration, telangiectasias, and the presence of a rolled border. Characteristics may vary for different clinical subtypes, which include nodular, superficial, morpheaform, and pigmented BCCs and fibroepithelioma of Pinkus (FEP).¹⁸ The anatomic location of BCC may favor the development of a particular subtype.

[View in Context](#)

LABELS

powered by
BIODIGITAL



Stage I tumor

Cases

Cases

LANGE Clinical Dermatology Cases



LANGE Clinical Dermatology Cases

Author(s): Carol Soutor; Maria K. Hordinsky

[Go to Book](#)

Clinical Dermatology cases presents challenging cases that are commonly seen in primary care. A brief history, a clinical photograph, differential diagnosis options and an explanation of the likely diagnosis are covered. These real-world cases present an opportunity for medical students, trainees and clinicians to improve their skills in the diagnosis and treatment of skin diseases

Cosmetic Concerns

[Cosmetic Concerns Case 1](#)

[Cosmetic Concerns Case 3](#)

[Cosmetic Concerns Case 2](#)

Diagnosis of Purpura

[The Differential Diagnosis of Purpura Case 1](#)

[The Differential Diagnosis of Purpura Case 3](#)

Cases는 1차 진료에서 흔히 볼 수 있는 까다로운 사례들을 제시하는 LANGE Clinical Dermatology Cases 에서 가져옵니다. 간략한 병력, 임상 사진, 감별 진단 옵션 및 가능한 진단에 대한 설명이 포함됩니다. 이러한 실제 사례는 의대생, 연수생 및 임상 의사가 피부 질환의 진단 및 치료 기술을 향상할 수 있는 기회를 제공합니다.

Patient Education Handouts

Patient Education Handouts

Adult Advisor

Medicines Advisor

Pediatric Advisor

Sign in to your MyAccess profile to add a logo and/or personal message to your Patient Handout.

Adult Advisor

Language: English

Chinese (Simplified)

Chinese (Traditional)

English

French

Korean

Portuguese (Brazilian)

0 A B C

K L M N O P Q R S T U V W X Y Z

A1C Test for D

 PDF

Abdominal M...

Patient Education Handouts

Adult Advisor

Medicines Advisor

Pediatric Advisor

Print Download PDF Email Customize

Achilles Tendon Injury

Adult Advisor 2021.2 © 2021 Change Healthcare LLC and/or one of its subsidiaries

KEY POINTS

- An Achilles tendon injury is stretching or tearing of the strong band of tissue that attaches your heel bone to the calf muscle.
- Change or stop doing the activities that cause pain until the injury heals.
- An Achilles tendon injury can be treated with special shoes or shoe inserts, exercise, [ice](#), and sometimes with medicine or surgery.

What is an Achilles tendon injury?

An Achilles tendon injury is a problem with the tendon that connects your heel bone to the calf muscle of your lower leg. Tendons are strong bands of tissue that attach muscle to bone. You use the Achilles tendon when you point your foot down and when you walk, run, or jump.

환자에게 질병에 대한 원인과 증상, 치료법을 소개해주는 핸드아웃으로, MyAccess 프로파일에 로그인하면 이 자료에 로그인 개인 메시지를 추가할 수 있습니다.

Study Tools : LANGE Clinical Dermatology Study Tools

LANGE Clinical Dermatology Study Tools

Cases

Lectures

Videos

- Unknown clinical cases with 48 self-assessment questions that cover challenging diagnostic and management problems.
- Eleven PowerPoint presentations that can be used by students and educators.
- Videos with detailed demonstrations of 7 common cutaneous diagnostic and surgical procedures.



Cases



Lectures



Videos

18 mins, 31 secs

Author(s) Carol Soutor, MD

Jump to:

1. Diagnosis and Management of Skin Disorders: Pearls and Pitfalls
2. Learning Objectives
3. Diagnosis in Dermatology
4. The Primary Lesion
5. Types of Primary Lesions
6. Types of Primary Lesions
7. Pitfalls in Identification of the Primary Lesion
8. Pitfalls in Identification of the Primary Lesion
9. Characteristics of Primary Lesions that May Aid in Diagnosis
10. Differential Diagnosis
11. Differential Diagnosis Based Only on the Primary Lesion(s)
12. Differential Diagnosis Based on Location(s) of Lesions
13. Categories of Dermatoses (Rashes)
14. Two Broad Disease Categories
15. Laboratory Confirmation of the Diagnosis
16. Common Laboratory Tests for

Pitfalls in Identification of the primary lesion

- Postinflammatory hyper- and hypopigmentation may obscure the primary lesion (Figure 9)
- The examination may take place too early or too late in an evolving skin disease such as herpes zoster (Figure 10)
- Treatment with topical steroids or topical antifungal creams may alter the characteristic appearance of the lesions

Figure 9

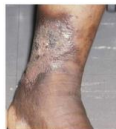
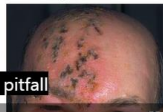
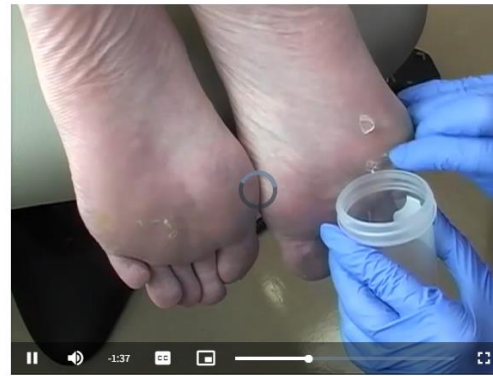Figure 10



Another thing that may be a pitfall

2 mins, 27 secs

Author(s) Carol Soutor, MD, Maria K. Hordinsky, MD



- * 까다로운 진단 및 관리 문제를 다루는 48개의 자체 평가 문항이 있는 알려지지 않은 임상 사례 제공
- * 학생과 교육자가 사용할 수 있는 11개의 파워포인트 프레젠테이션 제공
- * 일반적인 피부 진단 및 수술 절차를 자세히 보여주는 비디오 수록

Study Tools : Review Questions

Review Questions

BARNHILL'S Dermatopathology Challenge



Barnhill's Dermatopathology Challenge: Self-Assessment & Review

Garrett T. Desman, Raymond L. Barnhill

Copyright | Notice | Edit

Go to Book

"Go to Book" 버튼을 통해 해당 교재로 쉽게 돌아갈 수 있음. (해당되는 경우)

NOTE: A quiz may not include more than 250 questions. Quizzes cannot be saved mid-progress.

Create Random Quiz

10 of 403 available

Start Quiz

사용자는 단일 책 내의 모든 Q&A에서 랜덤 퀴즈를 바로 생성 가능

Create Custom Quiz

Generate a custom quiz from the topics below

Inflammatory Diseases of the Epidermis

0 of 55 available

Dermal-Based Inflammatory Diseases

0 of 30 available

Vesiculobullous Diseases

0 of 34 available

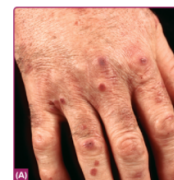Vasculitis and Related Disorders

집중 학습 원하는 사용자는 특정 주제 (있는 경우)에서 질문을 선택하여 퀴즈 생성 가능

Review Questions

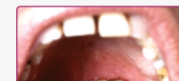
Question 2 of 10

A 43-year-old Caucasian male presents dyspnea as well as palpable purpura and a deep ulcer of the soft palate. Urinalysis reveals hematuria and proteinuria. Two skin biopsies are performed. The first biopsy reveals leukocytoclastic vasculitis, whereas the findings of the second biopsy are illustrated below. Direct immunofluorescence is negative for immunoglobulin deposition within vessels. Indirect immunofluorescence using the patient's serum and normal circulating neutrophils as a substrate reveals a diffuse cytoplasmic staining pattern. Which of the following diagnoses is CORRECT?



Source: Garrett T. Desman, Raymond L. Barnhill. Barnhill's Dermatopathology Challenge: Self-Assessment & Review. Copyright © McGraw-Hill Education. All rights reserved.

Reproduced, with permission, from Goldsmith LA, Katz SI, Gilchrist BA, Paller AS, Leffell DJ, Wolff K, eds. Fitzpatrick's Dermatology in General Medicine, 8th ed. New York, NY: McGraw-Hill Education; 2012.



Review of Medical Microbiology and Immunology, 14e>

Quiz Results

Your Score: 20 %

You answered 2 of 10 questions correctly.

Question 1: Incorrect

Crosses the placenta

- A IgM
- ✓ B IgG
- ✗ C IgA
- D IgE

문제풀이 후 결과 및 해설 제공

The correct answer is B. You answered C.

91% of users answered correctly.

Question 2: Incorrect

Each of the following statements concerning hepatitis C virus (HCV) and hepatitis D virus (HDV) is correct EXCEPT:

- A HCV is an RNA virus that causes post-transfusion hepatitis.
- B HDV is a defective virus that can replicate only in a cell that is also infected with hepatitis B virus.
- ✓ C HDV is transmitted primarily by the fecal-oral route.
- ✗ D People infected with HCV commonly become chronic carriers of HCV and are predisposed to hepatocellular carcinoma.

The correct answer is C. You answered D.

MyAccess(개인계정) 생성하기

학내 접속 시
자동으로
학교이름이
보여짐

McGraw Hill Medical | Support | Subscribe

ACCESS DermatologyDxRx™

Books | Quick Reference | Drugs | Multimedia | Cases | Patient Ed | Study Tools | About

AccessDermatologyDxRx | Search AccessDermatologyDxRx

Sign In | McGraw Hill Professional

Access Provided by: McGraw Hill Professional

[Sign in or Create a Free MyAccess Profile](#)

Sign Out

Search

GET ACCESS TO THIS RESOURCE

MyAccess Sign In

Username or Email

Password

Sign in

[Forgot Username?](#) [Forgot Password?](#)

[Sign in via OpenAthens](#)
[Sign in via Shibboleth](#)

Create a Free MyAccess Profile

[What is MyAccess?](#)

Get access to Review Questions.

Use your Institution's Access sites from anywhere.

Save your favorite content across all Access sites.

Discover

Modules

개인계정 생성
클릭

클릭

MyAccess(개인계정) 생성하기

Create a Free MyAccess Profile

If you have registered for a MyAccess profile on any of the Access sites, you can use the same MyAccess login credentials across all sites.
[Learn more about MyAccess](#)

Already have a profile? [Sign in](#)

* = Required Fields

First Name* Last Name*

Email Address*

Username*

Password* Passwords must be between 6 and 40 characters long (no whitespace), cannot contain characters #, &, and must contain:

Re-enter Password*

- at least one lowercase letter
- at least one uppercase letter
- at least one digit

Profession*
--Select--

Specialty
--Select--

☒ Would you like to receive special discounts and offers for McGraw-Hill Medical products and services?

Create Profile [Cancel](#)

이름, e-mail (필수입력)

ID/PW 등록 (필수입력)
우측 패스워드 생성 가이드 참조

직업(필수) 세부전공(선택) 입력

Create Account 클릭

<개인계정 생성 시 장점>

•모바일 기기 이용 가능

1) 모바일에서 개인계정 로그인 시 교외접속 없이 사용 가능

2) 학내 IP에서 로그인 시 90일간 모바일 이용 인증되며, 90일 동안 학내에서 한번도 이용하지 않을 경우 만료됨 (90일 이내 재로그인 시 자동연장)

•알람설정 가능 (신규컨텐츠 alert 등)

•북마크(즐거찾기) 기능

: 원하는 컨텐츠- 챗터, 도표, 비디오, 케이스 등

•원문 Print, e-mail 전송

•Image 저장

•Review Questions (Q&A) 문제풀이 및 결과 저장

MyAccess Folders

McGraw Hill Medical | Support | Subscribe

Sunmi Lee | McGraw Hill Professional

Access Provided by: McGraw Hill Professional

MyAccess Dashboard를 통해 프로젝트, 코스, 주제에 대한 자원을 별도로 저장할 수 있는 폴더 생성 가능

My Dashboard

My Favorites

Recently Viewed

My Review Questions

My Cases

My CME

Access your institution's subscriptions from anywhere. You have remote access from McGraw-Hill Professional for 90 days. [Learn More](#)

Sites Provided By: McGraw-Hill Professional

- AccessAnesthesiology
- AccessCardiology
- AccessEmergency Medicine
- AccessHemOnc
- AccessMedicina
- AccessMedicine
- AccessMedicine App
- AccessNeurology
- AccessObGyn
- AccessPediatrics
- AccessPharmacy
- AccessPhysiotherapy
- AccessSurgery
- Case Files Collection
- Clinical Sports Medicine Collection

My Favorites

- Figure 45-6: From Morgan & Mikhail's Clinical Anesthesiology, 5e > Chapter 45. Spinal, Epidural, & Caudal Blocks on AccessMedicine
- Figure 20-6: From CURRENT Diagnosis & Treatment: Physical Medicine & Rehabilitation > Pediatric Rehabilitation on AccessMedicine
- Lumbar Puncture Sitting Position: On AccessMedicine
- Case 6.07: From Graber and Wilbur's Family Medicine Examination and Board Review, 4th Edition on AccessMedicine

[View All Favorites](#)

My CME

Custom Curriculum

You have no active assignments at this time.

My CME

0.0 out of 20 CME Claimed in 2017

0.0 CME Credits In Progress >

0.0 CME Credits Eligible >

1 Unassigned Resources >

[Claim CME](#)

Aug 29,

10 Questions Score: 20%

Quiz on AccessMedicine taken Mar 09, 2017 07:37 AM

9 Questions Score: 33%

[View All Review Questions](#)

My Folders

- Study Plan: Contains 4 item(s)

[Go to Folders](#)

MyAccess Folders

My Dashboard My Favorites Recently Viewed Custom Curriculum My CME My Recent Activity

Search McGraw-Hill Medical

Favorites My Folders

Favorites Select All Add To Folder Download Figures Download Tables

Figure 45-6
From Morgan & Mikhail's Clinical Anesthesiology, 5e > Chapter 45. Spinal, Epidural, & Cerebrospinal Anesthesia

Figure 20-6
From CURRENT Diagnosis & Treatment: Physical Medicine & Rehabilitation, 4th Edition on AccessMedicine

Lumbar Puncture Sitting Position
On AccessMedicine

Case 6.07
From Graber and Wilbur's Family Medicine Examination and Board Review, 4th Edition on AccessMedicine

Traumatic Brain and Spinal Cord Injury
From Critical Care on AccessMedicine

Add to Folder
Select a folder to add this content to.

Study Plan

Create New Folder

Favorites My Folders

My Folders >

Study Plan Rename Folder

Select All Copy to Folder Download Figures Download Tables Remove Selected

Figure 20-6
From CURRENT Diagnosis & Treatment: Physical Medicine & Rehabilitation > Pediatric Rehabilitation on AccessMedicine

Lumbar Puncture Sitting Position
From Lumbar Puncture Sitting Position on AccessMedicine

Case 6.07
From Graber and Wilbur's Family Medicine Examination and Board Review, 4th Edition on AccessMedicine

Traumatic Brain and Spinal Cord Injury
From Critical Care on AccessMedicine

즐거찾기(Favorites) 탭에 저장되어 있는 항목들 중 원하는 콘텐츠를 체크 > "Add To Folder" 클릭 > 원하는 폴더 선택하여 이동